Research Article ISSN 2639-9512

Stem Cell & Regenerative Medicine

Extracorporeal Shock Wave Therapy (Eswt) For the Treatment of Chronic, Non-Healing Wounds: A Case Series

Belinda Marcus, MD, FACEP, CWS, PCHM*

Center for Vascular Intervention (CVI), Atlanta, GA.

*Correspondence:
Belinda Marcus, Center for Vascular Intervention (CVI), Atlanta, GA.

Received: 24 November 2020; **Accepted:** 04 December 2020

Citation: Marcus B. Extracorporeal Shock Wave Therapy (Eswt) For the Treatment of Chronic, Non-Healing Wounds: A Case Series. Stem Cells Regen Med. 2020; 4(2): 1-7.

ABSTRACT

Objective: *Extracorporeal shock wave therapy (ESWT) is a non-invasive therapy that involves generating shock waves (transient pressure disturbances that propagate rapidly in 3-dimensional space) outside the body and transmitting the acoustic energy inside the body to induce therapeutic effects. This case series examines the effectiveness of ESWT in treating chronic wounds of varying etiologies.*

Method: *In this retrospective case series, ESWT was applied to chronic, non- healing wounds. Patients were treated at a single center between December 2019 and March 2020. The criterion for application of ESWT was lack of progress toward wound healing despite standard treatments.*

Results: *We assessed six patients aged between 52 to 81 years old. Two patients had surgical wounds, three patients had leg ulcers of various etiologies, and one had a diabetic foot ulcer (DFU). All patients experienced progressive healing over multiple ESWT sessions. All six patients experienced complete wound closure following six to eleven applications of ESWT applied approximately once a week.*

Conclusion: *This series presents the effective use of ESWT in the treatment of chronic wounds of various etiologies.*

Keywords

Wound healing, Chronic wounds, Extracorporeal shock wave therapy (ESWT), OrthoGold, DermaGold, Case series.

Key points

- For the 6 patients, 6 to 11 weekly sessions of ESWT resulted in complete closure of chronic wounds of various etiologies.
- ESWT was administered in 10 to 15 minute, out-patient sessions to patients without anesthesia and with minimal discomfort.
- There were no adverse effects of ESWT.
- ESWT may reduce the need for amputation by speeding the healing of chronic wounds.

Reflective questions

How were the patients selected for inclusion in this case series? How generalizable are the results for these patients? What is the ideal ESWT protocol for each type of chronic wound? How do wound parameters/characteristics affect ESWT parameters?

Introduction

Chronic wounds, generally thought of as wounds that do not make normal progress towards healing within 4 weeks, are a common and costly health-care issue that consumes up to 3% of the healthcare budget in developed nations [1,2]. In the United States (US), chronic wounds affect 2.4 to 4.5 million individuals [1,3]. The prevalence of chronic wounds is increasing with the age of the population and the prevalence of chronic diseases which are more common in older adults. Diabetes, a chronic condition associated with diabetic foot ulcers (a common type of chronic wound), is estimated to be present in slightly over 25% of the US population ≥65 years old [4]. Common types of chronic wounds include

diabetic foot ulcers (DFUs), arterial and venous leg ulcers, and pressure ulcers (PUs), but chronic wounds may also result from surgery [5,6].

Wound healing includes 4 overlapping stages (hemostasis, inflammation, proliferation, and remodeling) as reviewed by Frykberg and Banks [7]. Hemostasis involves vasoconstriction and blood clotting immediately after the wound occurs. Inflammation, typically lasting about a week, occurs next and involves phagocytic cells that clean the wound and limit bacterial contamination as well as release growth factors and cytokines that recruit cells to come repair blood vessels and re-epithelialize the wound. During proliferation, angiogenesis and re-epithelialization occur and the wound is closed. During remodeling, after wound closure, the healing process is completed. Chronic wounds which fail to proceed through this process in an orderly and timely manner, often get stuck in the inflammation phase with high levels of pro-inflammatory cytokines, proteases, reactive oxygen species, senescent cells, infection, and a deficiency in amount and functionality of stem cells.

Chronic wounds can lead to complications such as infection and amputation, both of which drive up the cost of treatment. For example, studies of DFUs have shown that a chronic ulcer (one that lingers for >1 month) is more likely to become infected than a faster healing ulcer [8] and that infection is a leading cause of amputations related to DFUs [9]. Approximately 10% to 15% of DFUs are chronic [10], and approximately 25% of chronic DFUs result in an amputation [10]. Up to 50% of diabetic patients who have a major amputation die within 2 years [3]. Thus, it is clear that there is an unmet medical need to reduce complications associated with chronic wounds. Any treatment method that increases wound healing should also reduce the likelihood of complications of chronic wounds.

Chronic wound care is a specialty often practiced by a multidisciplinary team due to the complexity of patients who often have co-morbid conditions and require holistic management of both the patient and the wound [7]. Patients should be assessed for underlying conditions. Wounds should be assessed for diagnosis/etiology, characteristics (depth, extent, location, appearance, etc.), neurological condition, vascular condition, structural deformities, and infection. Standard of care includes management for any underlying issues as well as direct care for the chronic wounds which generally involves debridement (often surgical) and wound bed preparation followed by the application of dressings, offloading (may be surgical in case of structural deformities), revascularization and/or compression therapy as needed, and other topical therapies. If that fails, secondary treatments can include, but are not limited to, the use of extracorporeal shock wave therapy (ESWT), bioelectrical energy, radiofrequency energy, and ultrasound, specialized dressings, negative wound pressure therapy (NWPT), hyperbaric oxygen (HBO), and biological therapies, e.g. growth factors, skin grafts, extracellular matrices, and stem cells.

ESWT is a non-invasive therapy that involves generating shock waves (transient pressure disturbances that propagate rapidly in 3-dimensional space) outside the body and transmitting the acoustic energy inside the body to induce therapeutic effects. The shock waves generated by the medical device are applied to the target area using an applicator head, ultrasound gel as a contact medium, and a sterile barrier (e.g., plastic drape or cellulose) between the target and the applicator head. The mechanism of action for ESWT in wound healing is being studied and not entirely clear. However, in a wound, the various tissue layers vary in their acoustic impedance; these differences convert the acoustic energy of the shock waves to mechanical energy at the tissue interfaces and the process of mechano-transduction converts this mechanical energy into cellular regeneration (wound healing) [11].

Meta-analyses revealed that ESWT as an adjunct to wound treatment significantly accelerates healing. Zhang, et al. performed a meta-analysis of data from 301 patients in seven randomized controlled trials of multiple ESWT devices for the treatment of chronic wounds [12]. Relative to control therapy, ESWT improved the wound healing rate by 1.86-fold ($p = 0.0003$) and increased the percentage of the wound healing area by 30.46% ($p < 0.00001$). In addition, the wound healing time decreased by 19 days ($p < 0.00001$). These results are consistent with an existing large body of evidence supporting ESWT as a wound healing therapy (reviewed by Carmignano) [13] and further supported by two recent, randomized, sham-controlled, Phase 3 clinical trials that demonstrated faster healing time at 20 and 24 weeks [14].

This case series illustrates the use of ESWT, specifically the OrthoGold/DermaGold device in six patients with chronic non-healing wounds. All six patients had chronic wounds that remained open despite treatment that followed best practice guidelines. The goal of this study was to see if adding ESWT as adjunctive therapy would make the difference and get their wounds to close. The ESWT device used was recently approved by the FDA (November 2019) as a Class II device to be used in conjunction with standard care for the treatment of adults (≥ 22 years old) with chronic (>30 days), full-thickness DFUs with wound area ≤ 16 cm^2 which extend through the epidermis, dermis, tendon, or capsule without bone exposure.

Methods

This retrospective case series includes patients with chronic non-healing wounds treated with ESWT at the Center for Vascular Intervention (CVI), Atlanta, GA between December 2019 and March 2020. The criterion for application of ESWT was lack of progress toward healing despite prior treatment following best practice guidelines, as judged by the physician based on clinical characteristics such as wound bed appearance, wound margin status, changes in wound size, and response to previous treatment modalities. The patients in this case series have failed all previous treatment modalities and were considered at high risk for further surgical intervention or amputation.

All information presented was obtained from the patients' medical records retrospectively. Wound measurements, wound assessments, information on adjuvant therapies, and wound photographs were routinely collected to document progress. Patients were given instructions for wound management in accordance with standard care, including off-loading (varying methods). Wounds were routinely prepared by sharp debridement and confirmed to be free of clinical signs of infection before ESWT application. Consent was obtained for the use of these photographs and cases.

In all cases, ESWT application was performed using the OrthoGold/DermaGold device according to the manufacturer's instructions. The patients received between 6 and 11 sessions of ESWT. All ESWT sessions lasted approximately 10 to 15 minutes and were done in an outpatient setting. For almost all sessions, approximately 800 to 3,000 shocks/session and approximately 1,600 to 7,000 mJ/session were administered.

Results

A summary of all 6 cases is presented in Table 1.

Demographics and patient characteristics

This case series included six patients (3 female and 3 male) with various chronic wounds (postsurgical wounds [n=2], diabetic foot ulcer or DFU [n=1], and leg ulcers that originally started as bruises [n=1], blisters [n=1], or burn injury [n=1]). Ages of patients ranged from 52 to 81 years old.

Case study 1: Postsurgical wounds

Patient 1 was a 58-year-old female with non-healing postsurgical wounds. On 16 June 2019, she fell 10 feet off a ledge and sustained an open left distal tibia and fibula fracture and a left tibial pilon fracture.

On the date of the injury, the fractures were treated via incision and drainage (I&D) of soft tissue and bone, complex closure of the wounds, and application of a spanning external fixator. Two days later, the patient underwent open reduction internal fixation (ORIF) of the left lateral malleolus and the left fibula shaft, I&D of the left open fracture, and revision of the external fixator. On 29 June 2019, she underwent ORIF of the left pilon fracture and removal of the external fixator. The patient was placed on a postsurgical course of trimethoprim / sulfamethoxazole (Bactrim), which has been completed.

Prior to DermaGold ESWT treatment, X-rays showed stable alignment and stable fixation with hardware in a good position. At the time the patient presented at the CVI, there were multiple open areas that were draining, but she denied fevers, chills, and odor. Her pain score was 4 to 5 out of 10 with 10 being maximum pain.

The 1st DermaGold ESWT application was done on 16 December 2019 on the postsurgical wound that presented with lymphedema (Figure 1a). ESWT was done approximately every 7 days (q7d) for a total of 11 sessions. The number of shocks per session ranged from 800 to 1203 with 1680 to 3073 mJ delivered per session. The wound was closed after 5 sessions (Figure 1b) and stayed healed after 5 additional sessions (Figure 1c).

Figure 1: Case 1.

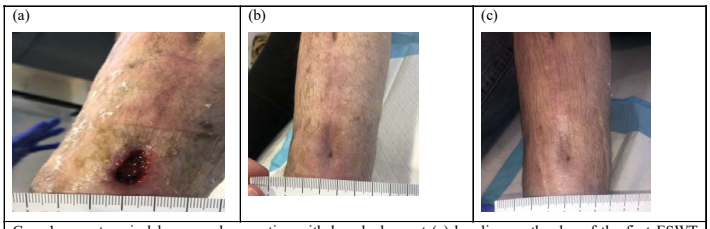

Case 1, a postsurgical leg wound presenting with lymphedema at (a) baseline on the day of the first ESWT session, (b) first observation of complete wound closure on the day of the 6th ESWT session, and (c) last observation on the day of the last of 11 ESWT sessions. All pictures were taken before the ESWT session on the same day.

Case study 2: bilateral lower-extremity (LE) ulcers

Patient 2 was a 55-year-old male with non-healing bilateral lower extremity (LE) ulcers. The patient reported that the ulcers had originally appeared as blisters in August 2018. The patient had a 30-year history of cigarette smoking.

Initial treatment performed by a dermatologist consisted of scraping of the ulcers. Additionally, multiple courses of oral antibiotics, oral gabapentin, and dapsone were prescribed as well as topical treatments, including Neosporin® (neomycin, polymyxin B, and bacitracin), Vaseline®, and clobetasol steroid cream. Despite these treatments, the ulcers progressed in size and pain. The patient reported pain for 9 months followed by increased pain over 3 weeks prior to the initial consultation at CVI. Vascular evaluation was performed and revealed severe tibioperoneal and pedal level occlusive peripheral artery disease (PAD) with threatened tissue and/or limb loss in the bilateral LEs. On 10 July 2019, he underwent percutaneous transluminal angioplasty (PTA) of the left mid anterior tibial artery and left distal peroneal artery. He was then admitted to the hospital for pain management and intravenous (IV) antibiotics. Upon discharge, the patient was given oral minocycline, which he was still taking as of December 2019. For cessation of smoking, the patient was placed on a nicotine patch in the hospital and then started on a course of oral treatment with CHANTIX® (varenicline). His last cigarette was on 10 July 2019.

He was then referred to an outpatient wound care / hyperbaric oxygen (HBO) center which placed him in bilateral Unna boots. The patient reported that wound treatment also consisted of scrubbing the ulcers, resulting in severe pain. His pain score was 8 to 9 out of 10. At the time of presentation at the CVI (December 2019), his left leg had been amputated below the knee (BKA) and he had a remaining painful ulcer on his right calf.

The 1st DermaGold ESWT application was done on 16 December 2019 on the right LE ulcer (Figure 2a). ESWT was done approximately q7d for a total of 10 sessions. The number of shocks per session for this ulcer ranged from 1600 to 3000 with 3,776 to

7,087 mJ delivered per session. The wound gradually healed over the course of ESWT (Figure 2b). Starting on 24 February 2020 (8th sessions), the area around the wound (peri-wound) was also treated with ESWT (1,000 to 1,002 shocks per session with 2,360 to 2,365 mJ delivered per session). The ulcer was partial thickness (PT) as of 9 March 2020 (day of last ESWT session) (Figure 2c).

Figure 2: Case 2.

Case 2, a right lower extremity (LE) ulcer at (a) baseline on the day of the 1st session of ESWT, (b) after 5 sessions of ESWT (halfway through the course of therapy), and (c) on the day of the last session of ESWT. All pictures were taken before the ESWT session on the same day.

Case study 3: postsurgical wounds

Patient 3 was a 60-year-old male with non-healing postsurgical wounds on the right foot. On 26 April 2019, he underwent debridement of plantar bony prominences on the mid-lateral column of the left foot; this wound closed. At a follow-up visit on 29 May 2019, the patient was diagnosed with an acute infection of the right 2nd toe and right midfoot with an abscess under the plantar fascia after I&D. The 2nd toe was subsequently amputated. He was undergoing meropenem infusion every evening via a right subclavian 2-lumen peripherally inserted central catheter (PICC) line at the time of presentation at the CVI. Due to the non-healing postsurgical wounds as well as suspicion of peripheral artery disease (PAD), the patient was referred to the CVI for additional evaluation and treatment. At the time the patient presented at the CVI, he had a persistent ulcer on the bottom of the right foot and a new ulcer on the left foot.

For the right foot, the 1st DermaGold ESWT session was done on 16 December 2019 (Figure 3a). ESWT was done approximately q7d for a total of 8 sessions. The number of shocks per session ranged from 819 to 2,000 with 1,794 to 4,720 mJ delivered per session. The wound was closed after 4 sessions (Figure 3b) and remained closed after 4 additional sessions (Figure 3c).

For the left foot, the 8 ESWT sessions were done on the same days as for the right foot. The first session occurred on 16 December 2019 (Figure 4a). The number of shocks per session ranged from 819 to 1,750 with 1,770 to 3,542 mJ delivered per session. The wound was closed after 3 sessions, re-opened after debridement between the 4th and 5th sessions of ESWT (Figure 4b), closed again by the day of the 6th session of ESWT, re-opened again between the last 2 ESWT sessions for debridement, received one last session of ESWT (Figure 4c), and was closed again by 15 days after the last ESWT session (Figure 4d).

Figure 3: Case 3 (Right Foot)

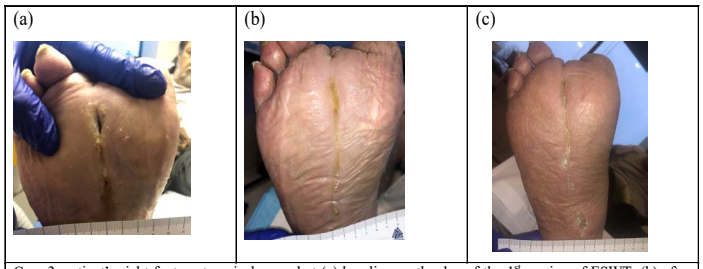

Case 3, patient's right foot postsurgical wound at (a) baseline on the day of the 1st session of ESWT, (b) after 4 sessions of ESWT (first observation of complete wound closure), and (c) on the day of the last session of ESWT. All pictures were taken before the ESWT session on the same day.

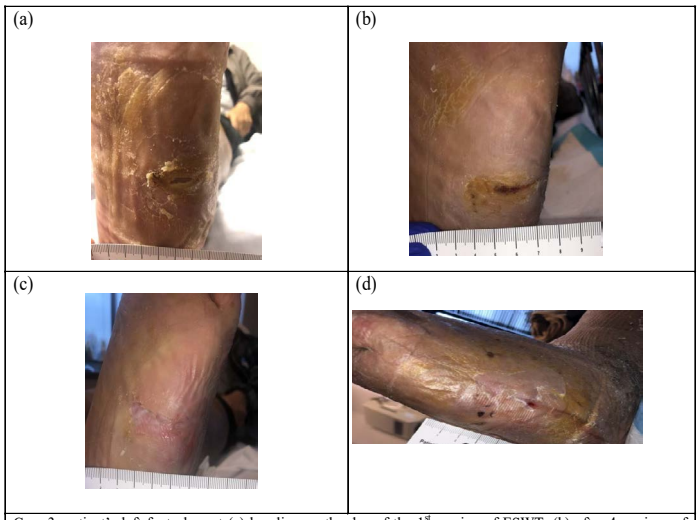

Case 3, patient's left foot ulcer at (a) baseline on the day of the 1st session of ESWT, (b) after 4 sessions of ESWT (wound re-opened because of a debridement procedure), (c) after another debridement and on the day of the last session of ESWT, and (d) 15 days after the last ESWT session. All pictures (except the one taken 15 days after the last ESWT session) were taken before the ESWT session on the same day.

Figure 4: Case 3 (Left Foot).

Case study 4: bilateral LE ulcers and edema

Patient 4 was an 81-year-old female with bilateral LE ulcers and edema. In March 2018, she sustained a severe burn caused by a space heater.

The patient subsequently underwent multiple skin grafts in April 2018, which were effective until November 2018 when the areas broke down. She was followed by wound care specialists 2 to 3 times per week (treatment and duration not otherwise specified) in a rehabilitation center and then discharged for follow up by home health. Keflex® (cephalexin) was prescribed for cellulitis and Norco® (hydrocodone bitartrate and acetaminophen) was prescribed for pain. The wounds reopened again and were treated with Xeroform™ and hydrocolloid dressings (date of wounds re-opening and duration of treatment not otherwise specified) without improvement. The patient reported having heel lift boots for her heel ulcers.

By the time of presentation to the CVI, she has been given multiple arterial and venous interventions to restore blood flow and improve bilateral LE edema. She presented to the CVI with 3 persistent ulcers to the left lower extremity (LLE) and her pain score was 7 out of 10.

For one of the ulcers, the 1st DermaGold ESWT application was done on 16 December 2019 (Figure 5a). ESWT was done every 7 days for a total of 6 sessions. After 2 sessions (each with 1,001 shocks with a total of 2,362 mJ delivered), the wound closed (Figure 5b). Two additional ESWT sessions were done on 6 January 2020 and 13 January 2020 (1,000 shocks with a total of 2,630 mJ delivered and 1,105 shocks with a total of 2,598 mJ delivered, respectively). Following these 2 sessions, the patient presented at a follow-up visit on 3 February 2020 with a reopened wound (Figure 5c) and worsening PAD per arterial doppler. Two more ESWT sessions were done on 3 February 2020 and 10 February 2020 (1,751 shocks with a total of 4,132 mJ delivered and 1,403 shocks with a total of 3,311 mJ delivered, respectively). The wound area decreased at subsequent follow-up visits, and achieved closure on 3 March 2020 (Figure 5d).

Figure 5: Case 4.

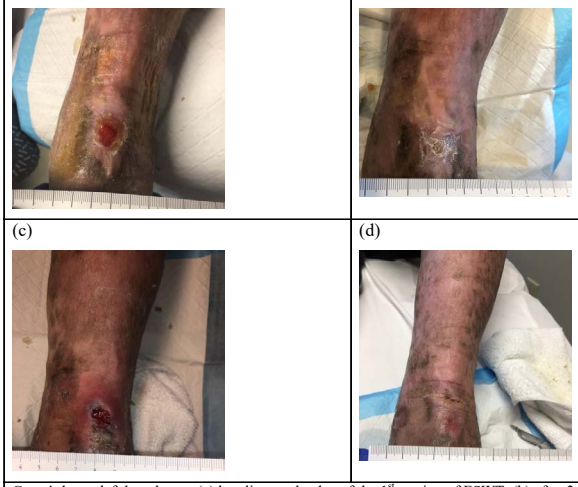

Case 4, lower left leg ulcer at (a) baseline on the day of the 1st session of ESWT, (b) after 2 sessions of ESWT (first observation of wound closure), (c) after wound re-opening approximately a month after initial observation of wound closure, and (d) after wound reclosure at approximately 3 weeks after the last ESWT session. All pictures (except the one taken approximately 3 weeks after the last ESWT session) were taken before the ESWT session on the same day.

Case study 5: bilateral LE ulcers

Patient 5 was a 52-year-old female with non-healing bilateral LE ulcers. The patient reported that the ulcers had originally appeared in December 2017 as bruises on the right LE and then progressed to the left LE. The patient had history of diabetes mellitus (type 2) and has been taking insulin.

Initial biopsies performed by a dermatologist confirmed pyoderma gangrenosum (PG), a disorder of the immune system resulting in large, painful ulcers. The patient failed multiple treatments including CellCept® (mycophenolate mofetil), methotrexate, and tacrolimus. She had been treating 7 PG ulcers with daily Dakin's solution and santyl without improvement, but 6 PG ulcers subsequently healed with skin grafting. She presented to the CVI with the 7th PG ulcer which had another wound (lateral) next to it (the two wounds were identified as #7 and Lat) for which she was taking steroid treatment (methylprednisolone 12 g per day) and Remicade® (infliximab) every 6 weeks. She reported ulcer pain and bilateral leg swelling but denied fever, chills, or odor.

The 1st DermaGold ESWT application was done on 16 December 2019 on ulcer #7 and the small wound lateral to it (Figure 6a). ESWT was done once a week for a total of 8 sessions with one or both ulcers treated at each session. The number of shocks per session for ulcer #7 ranged from 820 to 1,601 with 1935 to 3,778 mJ delivered per session. The number of shocks per session for the lateral ulcer ranged from 752 to 2,000 with 1,775 to 4,720 mJ delivered per session. Ulcer #7 was closed after 3 treatment sessions (Figure 6b) and the lateral ulcer wound was closed after 6 treatment sessions (Figure 6c). Both wounds remained closed on the day of the last ESWT session (Figure 6d).

Figure 6: Case 5.

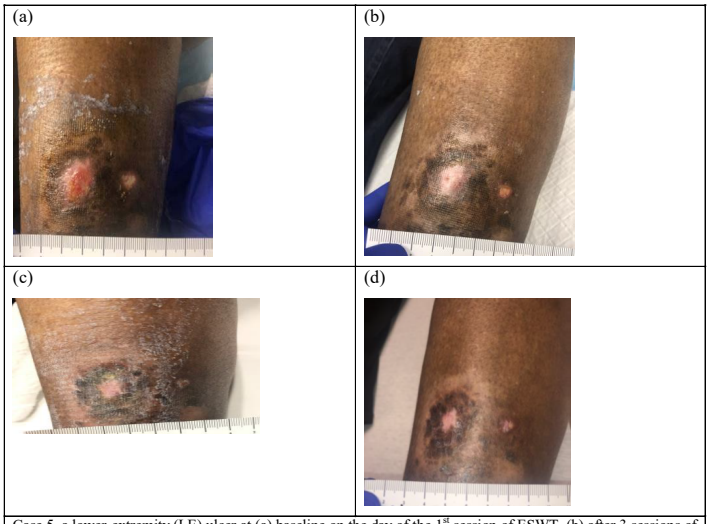

Case 5, a lower-extremity (LE) ulcer at (a) baseline on the day of the 1st session of ESWT, (b) after 3 sessions of ESWT (first observation of wound closure for ulcer #7), (c) after 6 sessions of ESWT (first observation of both wounds being closed), and (d) on the day of the last ESWT session. All pictures were taken before the ESWT session on the same day.

Case study 6: Bilateral LE ulcers

Patient 6 was a 52-year-old male with non-healing bilateral diabetic foot ulcers (DFUs). The patient reported that the ulcers developed after extensive walking in a zero-gravity boot while on vacation. The DFUs (2 right plantar ulcers and 1 left foot ulcer) had been debrided and dressed with mupirocin, and he was applying Silvadene® Cream 1% (silver sulfadiazine) to them. At the time of presentation to the CVI, the first right plantar ulcer had been open for 4 months, the second right plantar ulcer had been open for 3 months, and the left foot ulcer had been open for 1 month. He reported pain to be a 2 out of 10.

The patient also reported that DFUs had been reoccurring for approximately 3 years following a fracture of his left leg; however, the ulcers typically only appeared once per year. The patient had diabetes mellitus.

For the left foot DFU, the 1st DermaGold ESWT application was done on 23 December 2019 (Figure 7a). ESWT was done every 7 days for a total of 9 sessions. The number of shocks per session ranged from 758 to 3,000 with 1,789 to 7,080 mJ delivered per session. The wound was closed after 5 treatment sessions (Figure 7b) and remained closed on the day of the last session (Figure 7c).

Summary of cases

All six patients presented in this series achieved complete wound closure following 6 to 11 ESWT sessions administered approximately q7d (Table 1). ESWT was easy to apply in 10 to 15-minute outpatient sessions and there were no treatment-related side effects.

Figure 7: Case 6.

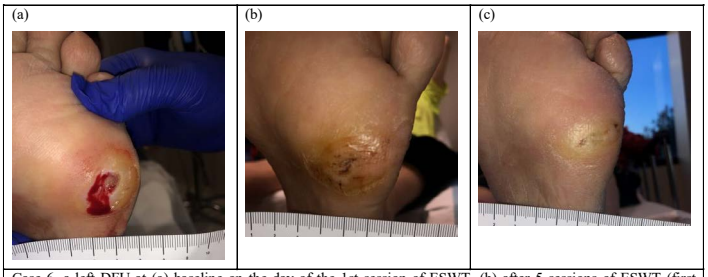

Case 6, a left DFU at (a) baseline on the day of the 1st session of ESWT, (b) after 5 sessions of ESWT (first observation of wound closure for the larger wound), and (c) on the day of the last ESWT session. All pictures (except for the one taken on 27 Jan 2020 in the absence of a ESWT session) were taken before the ESWT session on the same day.

Table 1: Summary of the Wounds in this Case Series.

Patient #	# of Wounds	Wound Type	Prior Therapies	Time Between Wound Occurrence and ESWT	Baseline Lesion Measurement (dimensions in cm)	Frequency of Planned ESWT Sessions	Total # of ESWT Sessions	# Shocks and Total Energy (Range per Session)	Final Wound Status
1	1	Postsurgical wound	Sulfamethoxazole and trimethoprim	Approximately 6 months	2.1 x 1 x 0.3	q7d	11	800 to 1203 shocks/ 1680 to 3073 mJ	Closed
2	1	Ulcer on right calf	Scraping, topical antibiotics, clobetasol steroid cream, and lotion Oral antibiotics, gabapentin, and dapsone IV antibiotics Oral minocycline and varenicline Scrubbing and Unna boots	Approximately 16 months	3.2 x 3.8 x 0.1	q7d	10	1600 to 3000 shocks/ 3776 to 7087 mJ	PT
3	2	Postsurgical wounds	Debridement (left foot) I&D and 2nd toe amputation (right foot) Meropenem infusion via PICC line	Approximately 8 months	Right foot: 1 x 0.1 x 0.2 Left foot: 0.3 x 1 x 0.1	q7d	8	Right foot: 819 to 2000 shocks/ 1794 to 4720 mJ Left foot: 819 to 1750 shocks/ 1770 to 3542 mJ	Closed
4	1	Ulcer on lower left leg	Skin grafts Wound care and rehabilitation Cefalexin, hydrocodone, acetaminophen Xeroform and hydrocolloid dressings Heel lift boots Arterial and venous surgical interventions	Approximately 21 months	1.4 x 1.1 x 0.1	q7d	6	1000 to 1751 shocks/ 3311 to 4132 mJ	Closed
5	2	Leg ulcers (identified as #7 and Lateral [Lat])	Mycophenolate Methotrexate Tacrolimus Dakin's solution and santyl Skin grafts Methylprednisolone and infliximab	Approximately 24 months	#7: 0.8 x 0.6 x 0.1 Lat: 0.6 x 0.8 x 0.1	q7d	8	Ulcer #7: 820 to 1601 shocks/ 1935 to 3778 mJ Lat: 752 to 2000 shocks/ 1775 to 4720 mJ	Closed
6	1	DFU on the left foot	Debridement and dressing with mupirocin Silver sulfadiazine cream	Unknown (patient didn't provide date for the vacation during which the wound started)	1.4 x 1.8 x 0.1	q7d	9	758 to 3000 shocks/ 1789 to 7080 mJ	Closed

Abx = antibiotic cream; b/l=bilateral; DFU = diabetic foot ulcer; ESWT= extracorporeal shock wave therapy; I&D = incision and drainage; IV = intravenous; LE = lower-extremity; PICC = peripherally inserted central catheter; PT = partial thickness; q7d = every 7 days.
Note: Only wounds with both pictures and ESWT session data are included in this case series. Some patients had additional wounds not in this table. Baseline wound measurement is the measurement taken on the day of the first ESWT session (measurement taken before ESWT administration).

Discussion/Conclusions

ESWT has been shown to produce a positive outcome on wound healing from the increase in blood supply, tissue regeneration, and neovascularization (reviewed by Carmignano and Dymarek, et al.) [13,15]. This case series demonstrates the potential of ESWT for effective treatment of patients with non-healing soft-tissue wounds and ulcers of various etiologies. The patients in this case series did not make satisfactory healing progress over the 6 months to 2 years before starting DermaGold ESWT despite receiving multiple prior treatment modalities following best practice guidelines. They were considered at high risk for further surgical intervention or amputation. Other characteristics of the cases in this series that may affect the course and outcome of wound treatment include wound severity, duration of wounds before ESWT treatment, patient age, and/or presence of comorbidities such as diabetes.

Wound care treatments that can speed recovery of lower extremity wounds may provide important benefits. As noted in the Introduction, the longer a wound remains unhealed, the more likely it is to have an infection that can lead to amputation [8,9]. ESWT is a cost-effective, fast (each session is approximately 10 to 15 minutes), out-patient treatment that can be done with minimal discomfort to the patient, without anesthesia, and with minimal side effects and may allow chronic wounds to heal faster, preventing/limiting costly hospitalizations and/or amputations and associated morbidity.

Limitations

Case series have inherent limitations. Results are from a single treatment center, which may lead to selection bias and limit generalizability to a wider population. Additionally, this was not a prospectively designed study in a selected population and lacked a control group; thus, the ability to draw conclusions about the effectiveness of the treatment may be limited.

Conclusion

This case series of patients with chronic non-healing wounds demonstrated that ESWT was associated with timely wound closure. ESWT, applied every 7 days for 6 to 11 sessions, was a convenient, out-patient (10 to 15-minute sessions) option without adverse effects. Outcomes, complete healing in all cases, are encouraging and suggest that incorporating ESWT into the wound care regimen for chronic non-healing wounds may be beneficial.

Acknowledgement

This study was supported by Softwave® Tissue Regeneration Technologies, LLC.

References

1. Richmond NA, Maderal AD, Vivas AC. Evidence-based management of common chronic lower extremity ulcers. Dermatol Ther. 2013; 26: 187-196.
2. Canadian Agency for Drugs and Technologies in Health. Optimal care of chronic, non-healing, lower extremity wounds: a review of clinical evidence and guidelines. Ottawa, ON, Canada, 2013.
3. Brownrigg JR, Apelqvist J, Bakker K, et al. Evidence-based management of PAD and the diabetic foot. Eur J Vasc Endovasc Surg. 2013; 45: 673-781.
4. Centers for Disease Control and Prevention. National Diabetes Statistics Report 2020: Estimates of Diabetes and Its Burden in the United States. Atlanta, GA, USA, 2020.
5. Hostetler SG, Xiang H, Gupta S, et al. Discharge patterns of injury-related hospitalizations with an acute wound in the United States. WOUNDS. 2006; 18: 340-351.
6. Nunan R, Harding KG, Martin P. Clinical challenges of chronic wounds: searching for an optimal animal model to recapitulate their complexity. Dis Model Mech. 2014; 7: 1205-1213.
7. Frykberg RG, Banks J. Challenges in the treatment of chronic wounds. Adv Wound Care. 2015; 4: 560-582.
8. Lipski BA, Berendt AR, Cornia PB, et al. 2012 Infectious Disease Society of America clinical practice guideline for the diagnosis and treatment of diabetic foot infections. Clin Infect Dis. 2012; 54: 132-173.
9. Wu S, Driver V, Wrobel J, et al. Foot ulcers in the diabetic patient, prevention and treatment. Vasc Health Risk Manag. 2007; 3: 65-76.
10. Pemayun TGD, Naibaho RM, Novitasari D, et al. Risk factors for lower extremity amputation in patients with diabetic foot ulcers: a hospital-based case–control study. Diabetic Foot & Ankle. 2015; 6: 29629.
11. Lohrer H, Nauck T, Korakakis V, et al. Historical ESWT paradigms are overcome: a narrative review. Biomed Res Int. 2016; 2016: 3850461.
12. Zhang L, Weng C, Zhao Z, et al. Extracorporeal shock wave therapy for chronic wounds: a systematic review and meta-analysis of randomized controlled trials. Wound Repair Regen. 2017; 25: 697-706.
13. Carmignano SM. Extracorporeal shock wave therapy in chronic wound care. In: Bernardo-Filho M, Cunha de Sá-Caputo D, Taiar R. (eds.) Physical therapy effectiveness. IntechOpen;12 Dec 2019.
14. Snyder R, Galiano R, Mayer P, et al. Diabetic foot ulcer treatment with focused shockwave therapy: two multicentre, prospective, controlled, double-blinded, randomized phase III clinical trials. J Wound Care. 2018; 27: 822-836.
15. Dymarek R, Halski T, Ptaszkowski, et al. Extracorporeal shock wave therapy as an adjunct wound treatment: a systematic review of the literature. Ostomy Wound Management. 2014; 60: 26-39.